

Brief Communication

Type I Anaphylactic Reaction Due to Contrast Induced Angioedema Causing Neck Swelling: Role of Sitting Fiberoptic Bronchoscopy in Emergent Intubation

Ali Dabbagh¹, Habibollah Saadat², Mahnoosh Foroughi², Samira Rajaei³, Reza Khajenouri¹, Farhad Solatpour¹, Abbas Arjmand Shabestari⁴, Taraneh Faghihi Langroudi⁴, Hamid Ghaderi³

Abstract

Contrast induced angioedema is a rapidly progressive state involving a number of organ systems, including the upper airway tract; which is usually a type I anaphylactic reaction also known as immediate hypersensitivity reaction. Prompt preservation of the respiratory tract is the cornerstone of this situation. The use of fiberoptic bronchoscope for tracheal intubation though very helpful, has some special considerations due to the anatomic distortions created by edema. This manuscript describes a patient with contrast induced angioedema managed successfully. Serum levels of immunoglobulin E were highly increased during the first hours after the event; while serum levels of complement were normal. However, rapid airway management and prophylactic intubation saved the patient and prevented the possible aftermath of airway obstruction.

Keywords: airway management, type I anaphylactic reaction, angioedema, fiberoptic bronchoscope

Please cite this article as: Dabbagh A, Saadat H, Foroughi M, Rajaei S, Khajenouri R, Solatpour F, et al. Type I Anaphylactic Reaction Due to Contrast Induced Angioedema Causing Neck Swelling: Role of Sitting Fiberoptic Bronchoscopy in Emergent Intubation. *J Cell Mol Anesth.* 2016;1(3):120-5.

Introduction

Difficult airway management is the "anesthesiologists' nightmare" (1-3) with many techniques, approaches and algorithms being proposed for predicting and defying this potential fatal event (3-13). When our tries for intubation would not be successful after three or four trials, there would be a critical situation, since the resulting airway trauma and edema aggravates the problem to create finally a very "critical airway event" (14). The incidence of difficult airway is low being about 1-8% of general anesthetics (15). But the problem is that its severity is so much life threatening that even the least possibility for its occurrence is a real threat. This is while difficult

airway in emergency situations makes a real catastrophe, especially when associated with "cannot ventilate, cannot intubate" which may possibly lead to potential neurological damage or even death (16-18). Here a case of difficult intubation with specific focus on cellular and molecular mechanisms of the disease is presented.

Brief Report

A 52-years old man with underlying coronary artery disease and diabetes mellitus underwent angiography in the catheterization lab of a university hospital. Before angiography, the Doppler ultrasonography revealed the left carotid as totally

1. Anesthesiology Research Center, Shahid Beheshti University of Medical Sciences, Tehran, Iran
2. Cardiology Research Center, Shahid Beheshti University of Medical Sciences, Tehran, Iran
3. Immunology Department, Tehran University of Medical Sciences, Tehran, Iran
4. Radiology Department, Shahid Beheshti University of Medical Sciences, Tehran, Iran

Corresponding Author:

Ali Dabbagh, MD; Associate Professor, Anesthesiology Research Center, Shahid Beheshti University of Medical Sciences, Tehran, Iran.
Tel: (+98) 912197 2368; Fax: (+98) 2122074101;
Email: alidabbagh@yahoo.com
Received: April 15, 2016
Accepted: July 15, 2016

occluded and the right one with mild obstruction. The patient underwent carotid angiography for exact determination and possible stenting of the right carotid. Afterwards, the patient was transferred to the coronary care unit.

2 to 3 hours after carotid angiography, the patient started a unilateral right sided swelling of the face extending from the eye to the lower neck. Little by little the patient swelling increased leading to some degrees of respiratory distress accompanied with severe dyspnea, sense of being choked, nausea, vomiting, and inability to swallow leading to drooling.

The patient had now an SpO₂ of 96% with supplementary nasal oxygen. While the results of bedside Doppler assessments of carotid arteries were normal, the rapid expansion of the left side and its unilateral nature created a doubt for possible carotid puncture and hematoma formation; so, to rule out this differential diagnosis an emergent axial CT scanning was requested promptly. Then, the patient was transferred emergently to the CT scanning department while the emergency intubation and tracheotomy set were available and the patient was monitored. The results demonstrated diffuse swelling of the soft tissues, with a very widespread involvement starting from the nasopharyngeal mucosa extending to the neck

and upper thoracic cuts demonstrating a considerable pressure effect on other parts of the neck and upper airways; the edema and swelling displaced the upper airway tract to the left, starting from base of the nasopharynx (and left sided paranasal sinuses) extending to the distal part of the trachea at the lower level of thyroid cartilage (Figures 1 to 3).

Due to the increasing severity of edema and dyspnea, the medical care team decided for prophylactic intubation of the patient. Since the upper airway anatomy demonstrated huge distortion accompanied with increasing edema of tongue and lips, we decided to intubate the patient in a sitting position using fiberoptic bronchoscope. After primary explanation, assurance and taking informed consent, the upper airway was locally anesthetized using 2% lidocaine spray, but oral intubation using fiberoptic bronchoscopy failed. Due to severe edema of the right nasal passage, nasal cavity and nasopharynx (Figure 3) the left nasal passage was chosen for nasal intubation. The left nasal cavity was first anesthetized; but there was difficulty for administration of lidocaine spray since the patient was under treatment with a maintenance dose of anticoagulant. A combination of lidocaine plus phenylephrine on cotton swab was administered on the anterior nares area, the anterior

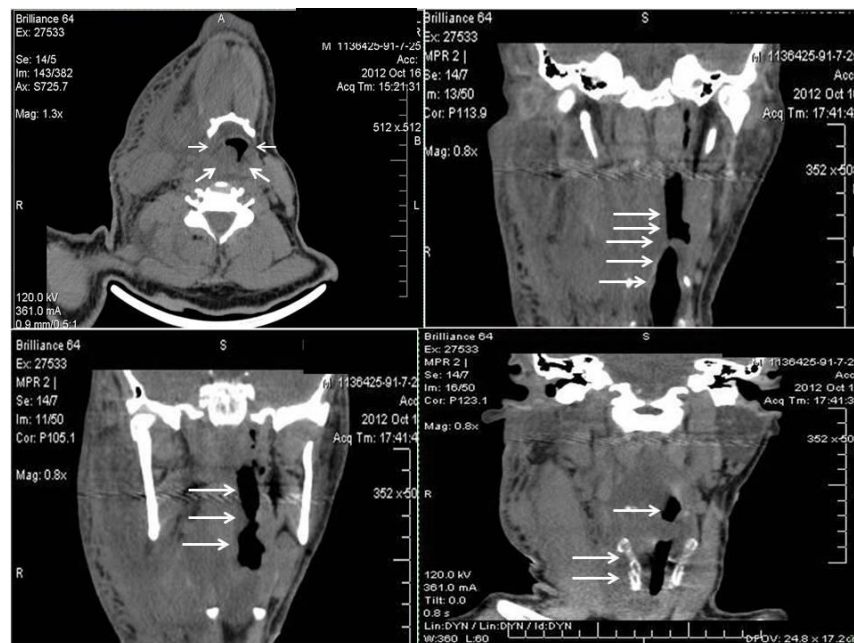

Figure 1. Horizontal CT scanning of the skull base demonstrating obstruction of the left nasal cavity due to edema with full involvement of the ethmoid area and partial involvement of the maxillary sinus; the lower left cut demonstrates full involvement of the left nasal cavity mucosa in a coronal view.

ethmoidal nerves; and sphenopalatine ganglion. A number 7 cuffed tracheal tube was passed through the nasal cavity to the trachea over the fiberoptic bronchoscope; its passage was preceded by direct visualization and approval of the vocal cords and then, the trachea; due to patient dyspnea, bronchoscopy was done in sitting position (Figure 4). The vocal cords had changed from their normal status to severely enlarged and edematous objects partially occluding the upper airway at the entrance of the trachea in concordance with the CT scan assessment (Figures 1 to 3). The tube was checked regarding ventilation; it was now that the patient was relieved of dyspnea. Pulse oxymeter demonstrated a saturation of 96% and the hemodynamic status was normal.

After about 30 minutes, the saturation gradually started falling down, which reached to about 80%,

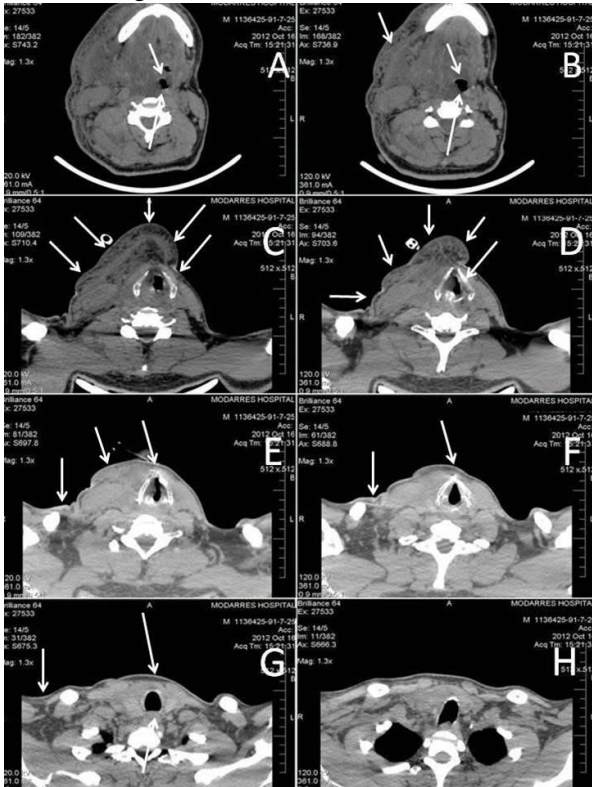


Figure 2. Coronal CT scanning of the nasopharynx and neck demonstrating near obstruction of the upper airway especially in the nasopharynx and hypopharynx due to edema; parts of the hypopharynx are going to be near totally obstructed; the upper left cut demonstrates the horizontal cut of the hypopharynx at the level of the hyoid bone; marked deviation of the airway from midline is demonstrated with arrows.

while the patient was receiving supplementary oxygen through the tracheal tube and then, was mechanically ventilated; meanwhile, the left side of the face started swelling, creating subcutaneous emphysema accompanied with decreased pulmonary sounds. An emergency chest X ray was performed which showed bilateral pneumothorax (Figure 5). Left side chest tube was inserted in a few minutes by the standby surgeons that revealed the respiratory problems immediately. The pulse oxymeter showed a saturation of 98% under mechanical ventilation but due to suspicious air in the right side, the right side chest tube was also inserted. For both the chest tubes, a sudden “hiss” sound of air leakage out of the chest was heard immediately.

A series of lab exams were done to check IgE and serum complements which showed that serum levels of IgE were highly increased during the first hours after the event; while serum levels of complement were normal during the aftermath and did not increase during the next days.

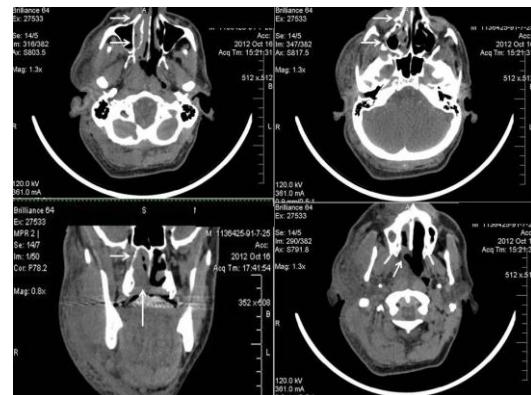


Figure 3. Horizontal CT scanning of the neck (starting from skull base to the upper thorax) demonstrating obstruction of the left nasal cavity due to severe mucosal edema; A & B are the lower level of the mandible, C & D show critical airway obstruction at the level of the thyroid cartilage, G & H are the distal part of edema and swelling. Note the pressure effect of angioedema in from A to H which has displaced the anatomy from left to right with marked deviation of the airway from midline demonstrated with arrows.

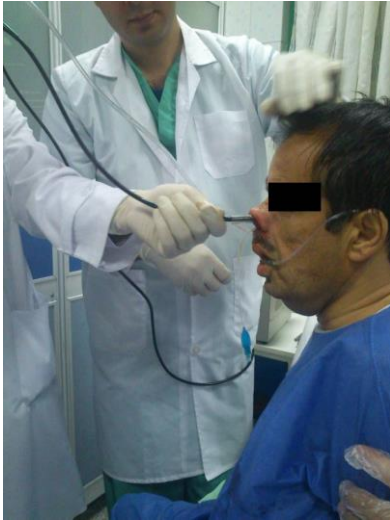

Figure 4. Fiberoptic bronchoscopy and intubation by the team in sitting position.

During the next 48 hours, the patient recovered gradually; the right sided edema was decreased and the left sided subcutaneous emphysema faded. The patient tolerated the respiratory weaning process having a spontaneous breathing being aided with 5 cmH₂O positive end expiratory pressure (PEEP) leading to total disconnection from mechanical ventilation. At the end of the 48 hours period, after total separation from mechanical ventilation, the pilot cuff of the tracheal tube was emptied; leaving the patient on spontaneous respiration for another 24 hours while having the tube. Per patient need, local sterile lidocaine solution was administered into the tracheal tube to make it tolerable for the patient while his pain scores never raised more

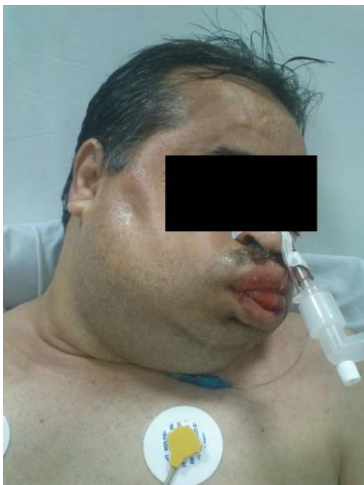

Figure 5. Successful left nasal intubation; note enlargement and protrusion of tongue.

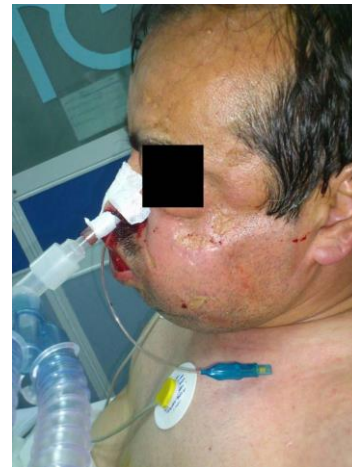

Figure 6. Right side subcutaneous emphysema occurring minutes after intubation extending to the right eye area.

than 3 of 10 on a visual analog pain scale.

The patient was examined after 24 hours, which showed positive and free air leakage test around the tracheal tube. The respiratory status was normal and the patient was extubated; in a situation that he did not have any edema, swelling, or subcutaneous emphysema.

He tolerated the next day without any problem while after 48 hours dyspnea started which was associated with a ground glass appearance of the chest. He was again intubated after 24 hours but this time, intubation was accompanied with normal anatomy and

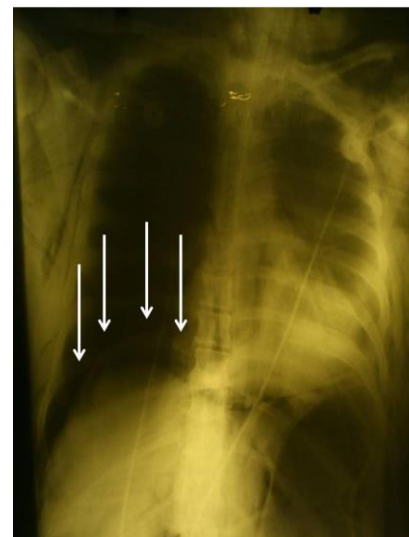


Figure 7. Posterior-anterior chest X ray demonstrating air in the right thorax; the arrows mark the right hemidiaphragm.

was done orally. 48 hours of supportive mechanical ventilation helped the lungs improve and the patient was extubated. He was under intensive support for another 24 hours and was transferred to the ordinary ward (which lasted for one week of supportive care). Finally, after 2 more days, he was discharged with no residual defects leaving hospital for his home.

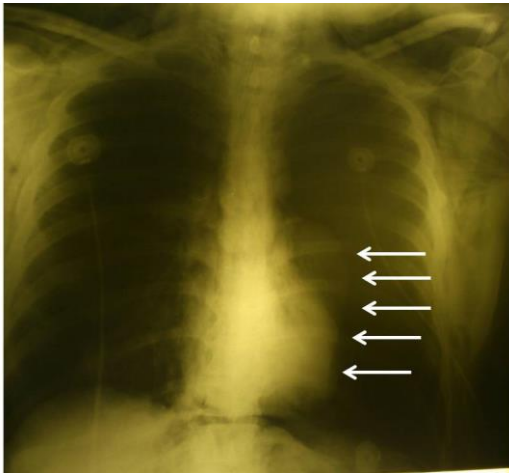


Figure 8. Posterior-anterior chest X ray demonstrating air in the left thorax; the arrows mark the silhouette of air with the compressed left lung.

Discussion

Angioedema due to the contrast agents is a type I hypersensitivity reaction; so, it is not a delayed immunologic event and is associated with very high levels of IgE, release of histamine and bradykinin and a number of other mediators from mast cells and basophils; clinically, the upper airway tract is often involved creating a dramatic clinical presentation with potentially life threatening airway obstruction, unless very rapid and prophylactic measures are promptly performed. Since involvement of the tongue is a predominant characteristic, oral or nasal intubation would be very difficult (19). A very similar pattern was also seen in the current patient and the rapid intubation helped us prevent critical airway obstruction; so the patient was saved.

The contrast agents are being used for many decades since 1920's with their known complications though the risk of these complications has been decreased dramatically; among all these

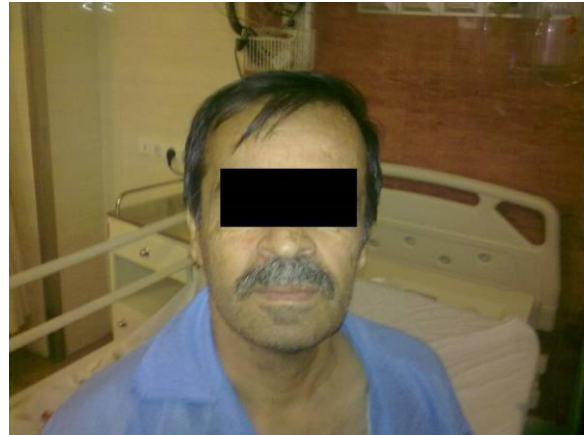

Figure 9. The patient just before discharge with resolved left and right lesions.

complications, contrast induced anaphylactoid reaction, though very rare, is really lethal if not treated immediately (19-20). These anaphylactoid reactions are due to histamine release and not immune mediated, so they have a very rapid course, especially when they are predominant in the head and neck area like the current patient occurring after carotid angiography. Usually these symptoms would be cleared after treatment after 48 to 72 hours, even to 1 week (21-25). Of course, the pattern of angioedema was seen unilaterally in this patient.

However, similar clinical presentation of angioedema after allergic reactions (for example due to the effects of angiotensin-converting enzyme inhibitors (19) or renin-angiotensin inhibitors (22) has been reported with very poor clinical outcomes: abrupt onset of obstructive angioedema; change in patient words and speech, severe edema of the larynx and tongue in less than 4 hours are described as the primary manifestations of the case with "airway obstruction, unsuccessful oral intubation, difficult tracheostomy and finally death" described as the final stages of the case report (24). Steroids, diphenhydramine, nonionic contrast media, subcutaneous epinephrine leading to treatments of shock including intravenous epinephrine and large amounts of intravenous normal saline. The reactions are a wide range starting from urticaria, accompanied with different degrees of nausea and vomiting leading to reactions such as angioedema, oral and laryngeal edema and finally acute airway compromise which mandates immediate airway management (20, 25).

Conclusion

Finally, the current patient demonstrated the role of airway protection in saving disease states that could threaten the life of patients with angioedema. Fiberoptic bronchoscopy would have a central role in saving the lives of patients who have critical events involving their airway, especially when distortion of the normal anatomy is encountered.

Acknowledgment

The authors would like to acknowledge the very kind efforts made by all their colleagues, including the physicians, nurses and technicians of the Modarres hospital, in critical care, anesthesiology, cardiology and radiology units for their kind cooperation in handling the patient.

Conflicts of Interest

None of the authors have any conflict of interest.

References

- Dabbagh A, Mobasseri N, Elyasi H, Gharaei B, Fathololumi M, Ghasemi M, et al. A rapidly enlarging neck mass: the role of the sitting position in fiberoptic bronchoscopy for difficult intubation. *Anesth Analg*. 2008;107(5):1627-9.
- Dabbagh A, Rad MP, Daneshmand A. The relationship between night time snoring and cormack and lehane grading. *Acta Anaesthesiol Taiwan*. 2010;48(4):172-3.
- Eberhart LH, Arndt C, Cierpka T, Schwanekamp J, Wulf H, Putzke C. The reliability and validity of the upper lip bite test compared with the Mallampati classification to predict difficult laryngoscopy: an external prospective evaluation. *Anesth Analg*. 2005;101(1):284-9.
- Khan ZH, Kashfi A, Ebrahimkhani E. A comparison of the upper lip bite test (a simple new technique) with modified Mallampati classification in predicting difficulty in endotracheal intubation: a prospective blinded study. *Anesth Analg*. 2003;96(2):595-9.
- Sharma D, Prabhakar H, Bithal PK, Ali Z, Singh GP, Rath GP, et al. Predicting difficult laryngoscopy in acromegaly: a comparison of upper lip bite test with modified Mallampati classification. *J Neurosurg Anesthesiol*. 2010;22(2):138-43.
- Pearce A. Evaluation of the airway and preparation for difficulty. *Best Pract Res Clin Anaesthesiol*. 2005;19(4):559-79.
- Langeron O, Amour J, Vivien B, Aubrun F. Clinical review: management of difficult airways. *Crit Care*. 2006;10(6):243.
- El-Orbany M, Woehlck HJ. Difficult mask ventilation. *Anesth Analg*. 2009;109(6):1870-80.
- Hernandez MR, Klock PA, Jr., Ovassapian A. Evolution of the extraglottic airway: a review of its history, applications, and practical tips for success. *Anesth Analg*. 2012;114(2):349-68.
- Mhyre JM, Healy D. The unanticipated difficult intubation in obstetrics. *Anesth Analg*. 2011;112(3):648-52.
- Lee A, Fan LT, Gin T, Karmakar MK, Ngan Kee WD. A systematic review (meta-analysis) of the accuracy of the Mallampati tests to predict the difficult airway. *Anesth Analg*. 2006;102(6):1867-78.
- Practice guidelines for management of the difficult airway: an updated report by the American Society of Anesthesiologists Task Force on Management of the Difficult Airway. *Anesthesiology*. 2003;98(5):1269-77.
- Frova G, Sorbello M. Algorithms for difficult airway management: a review. *Minerva Anesthesiol*. 2009;75(4):201-9.
- Rich JM. Recognition and management of the difficult airway with special emphasis on the intubating LMA-Fastrach/whistle technique: a brief review with case reports. *Proc (Bayl Univ Med Cent)*. 2005;18(3):220-7.
- Crosby ET, Cooper RM, Douglas MJ, Doyle DJ, Hung OR, Labrecque P, et al. The unanticipated difficult airway with recommendations for management. *Can J Anaesth*. 1998;45(8):757-76.
- Rich JM, Mason AM, Bey TA, Krafft P, Frass M. The critical airway, rescue ventilation, and the combitube: Part 2. *AANA J*. 2004;72(2):115-24.
- Rich JM, Mason AM, Bey TA, Krafft P, Frass M. The critical airway, rescue ventilation, and the combitube: Part 1. *AANA J*. 2004;72(1):17-27.
- Rich JM, Mason AM, Ramsay MA. AANA journal course: update for nurse anesthetists. The SLAM Emergency Airway Flowchart: a new guide for advanced airway practitioners. *AANA J*. 2004;72(6):431-9.
- Roberts JR, Wuerz RC. Clinical characteristics of angiotensin-converting enzyme inhibitor-induced angioedema. *Ann Emerg Med*. 1991;20(5):555-8.
- Nayak KR, White AA, Cavendish JJ, Barker CM, Kandzari DE. Anaphylactoid reactions to radiocontrast agents: prevention and treatment in the cardiac catheterization laboratory. *J Invasive Cardiol*. 2009;21(10):548-51.
- Olesen AL, Tollund C, Sondergaard I, Strom JJ. [Life-threatening angioedema associated with ACE inhibitor treatment]. *Ugeskr Laeger*. 2003;165(10):1041-2.
- Stojiljkovic L. Renin-angiotensin system inhibitors and angioedema: anesthetic implications. *Curr Opin Anaesthesiol*. 2012;25(3):356-62.
- Borum ML, Howard DE. Hereditary angioedema. Complex symptoms can make diagnosis difficult. *Postgrad Med*. 1998;103(4):251, 5-6.
- Jason DR. Fatal angioedema associated with captopril. *J Forensic Sci*. 1992;37(5):1418-21.
- Goss JE, Chambers CE, Heupler FA, Jr. Systemic anaphylactoid reactions to iodinated contrast media during cardiac catheterization procedures: guidelines for prevention, diagnosis, and treatment. Laboratory Performance Standards Committee of the Society for Cardiac Angiography and Interventions. *Cathet Cardiovasc Diagn*. 1995;34(2):99-104.